

Macular hole, commotio retinae, and choroidal rupture after blunt eye injury

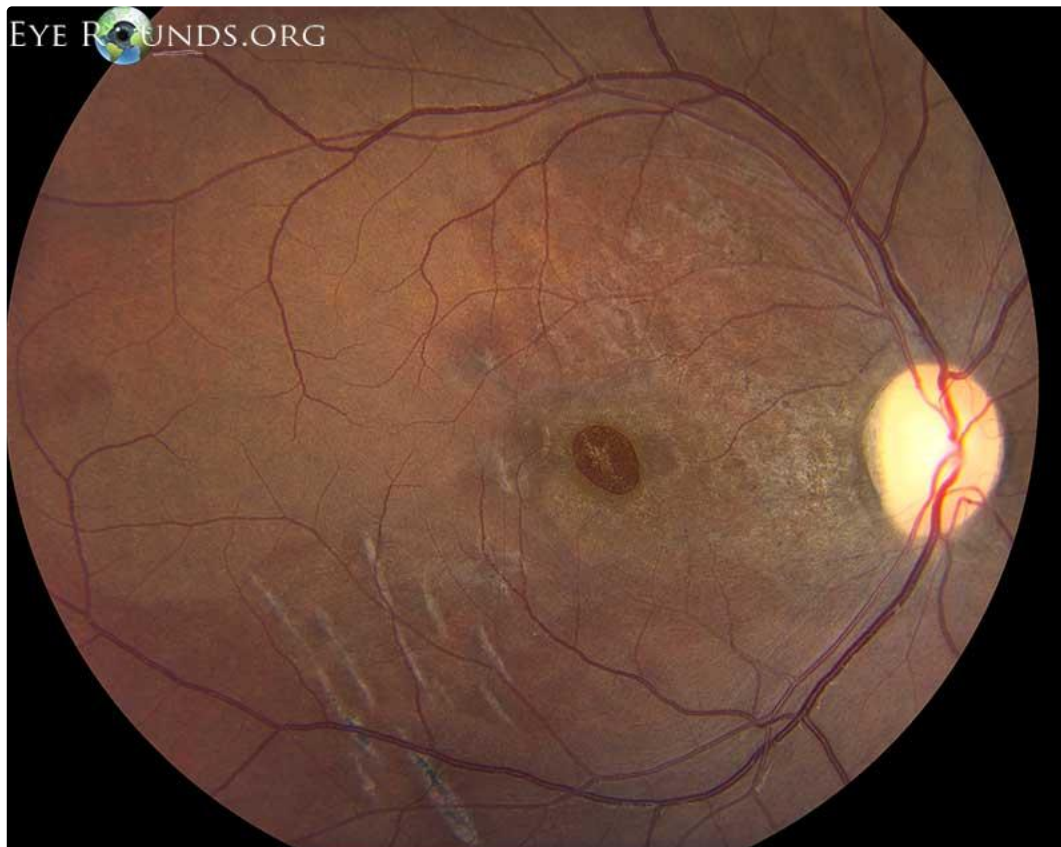
Category(ies): Retina, Vitreous, Trauma

Contributor: [Jesse Vislisel, MD](#)

Photographer: Cindy Montague, CRA



This patient experienced blunt eye injury during a severe motor vehicle accident and has several retinal sequelae from the incident. Notable findings include a full-thickness macular hole and multiple arc-shaped choroidal ruptures in the inferotemporal macula. There is also a large area of hypopigmentation secondary to commotio retinae, or loss of retinal transparency secondary to photoreceptor disorganization.



[Enlarge](#) [Download](#)

Image Permissions:



Address

University of Iowa
Roy J. and Lucille A. Carver College
of Medicine
Department of Ophthalmology and
Visual Sciences
200 Hawkins Drive
Iowa City, IA 52242

[Support Us](#)

Legal

Copyright © 2019 The University of
Iowa. All Rights Reserved
[Report an issue with this page](#)
[Web Privacy Policy](#) |
[Nondiscrimination Statement](#)

Related Links

[Cataract Surgery for Greenhorns](#)
[EyeTransillumination](#)
[Gonioscopy.org](#)
[Iowa Glaucoma Curriculum](#)
[Iowa Wet Lab](#)
[Patient Information](#)
[Stone Rounds](#)
[The Best Hits Bookshelf](#)

EyeRounds Social Media

Follow



Receive notification of new cases,
[sign up here](#)
[Contact Us](#)
[Submit a Suggestion](#)